

Note

Investigating the presence of blood in dairy milk by using a simple device  
for quantitative determination of red blood cells

Kenji Nekomoto<sup>1</sup>, Yume Yoshida<sup>1</sup>, Honoka Ohshiro<sup>1</sup>, Yui Sasajima<sup>1</sup>, Takashi Sugawara<sup>2</sup>,  
Noriyuki Shinomiya<sup>2</sup> and Tomohisa Tamura<sup>2</sup>

<sup>1</sup> College of Agriculture, Food and Environment Sciences, Rakuno Gakuen University, Bunkyo-dai, Ebetsu,  
Hokkaido, 069-8501

<sup>2</sup> Tokachi-Foundation, Obihiro, Hokkaido, 080-2462

**Abstract** Reddish or pinkish milk contaminated with red blood cells due to diapedesis of the mammary gland is a rare occurrence at dairy farms. There is not much information about the frequency and causal factors of haemolactia (i.e., the presence of blood in milk). In this study, haemolactia in dairy cows was investigated by using a device for quantitative determination of blood in milk, which is being developed by the Tokachi Foundation. Milk samples (colostrum) from 4 cows and pinkish milk samples from 2 cows with mastitis or an external wound to the udder were obtained at two dairy farms in eastern Hokkaido between July and November 2019. The average concentrations of blood in the colostrum on the 3rd day after calving was  $0.0028 \pm 0.0027\%$ , which is less than the 0.01% detection limit of visual inspection. The concentration of blood in the milk from the cow with mastitis ranged from 0.25% to 0.0012% over the 4 days, which gave the milk a pinkish tinge. The concentration of blood in the milk from the cow with an external wound to the udder ranged from 0.24% to 0.011% over 4 days; this milk was not noticeably pink on the 4th day by visual inspection.

**Key words:** blood in milk, haemolactia, colostrum, mastitis, dairy farm

Receipt of Ms: 09.09.2020. Accepted: 10.26.2020.

Journal of Animal Production Environment Science No.20(1) pp10–15. 2021

The page has been revised due to the publication as a No19/20 merger issue. No19/20 (1) pp50–55. 2021

### Introduction

Reddish or pinkish milk contaminated with red blood cells (RBCs) due to diapedesis of the mammary gland is a rare occurrence at dairy farms. Such contamination in bulk tanks or tankers is rarer still because haemolactia (i.e., the presence of blood in milk) is usually detected by the practice of forestripping, which involves manually removing a few strips of milk from each teat to detect signs of abnormal milk, before attaching the milking unit.

However, there is not much information about the frequency and causal factors of haemolactia because

dairy farmers generally dispose of any milk contaminated with blood. Over 5 years, there were 14 recorded cases from 385 farms in the Tohoku region of accidental blood contamination in collecting vehicles leading to disposal of few tons of milk, which is financially detrimental to dairy farmers. Haemolactia is the third most common reason for farmers to dispose of multiple tons of milk, following antibiotic contamination and bacterial contamination [5].

The causes of haemolactia are diapedesis due to hyperaemia during the post-calving period, an

## Presence of blood in cow's milk

external wound such as udder bruising, and inflammatory disease such as mastitis [2,7]. Visually confirming the colour of the milk or the presence of visible RBC sedimentation by centrifuging the milk are common methods for detecting haemolactia [6]. It has been reported that the rate of haemolactia in cows just after calving was 13.1% when using highly accurate detection methods such as centrifugation of the milk [2].

At dairy processing facilities, the main method for detecting blood in milk having only a slight reddish or pinkish tinge distributed from each dairy farm was visual confirmation by a skilled worker; however, this method results in inconsistent results due to individual differences among inspectors. In Japan, the limit for blood in milk is set at 0.01% [4], a level that cannot be detected visually (i.e., occult blood). Centrifugation of milk can detect occult blood, but this inspection method requires time to obtain results and is therefore not practical for dairy farms and processing facilities, which operate under tight production schedules. In addition, occult blood cannot be detected by centrifugation under haemolysis conditions.

From the reasons mentioned above, it is necessary to be able to detect blood in milk easily and irrespective of the skill of individual inspectors. Therefore, a simpler method for quantitatively determining the presence and amount of blood in milk is needed for dairy production sites. In this study, haemolactia in dairy cows was investigated by using a device for quantitative determination of blood in milk under development by the Tokachi Foundation. For the investigation, data were obtained on the daily change in concentration of blood in cow's milk, in contrast to previous basic investigations, which assessed only by the presence of some blood without quantification.

### Materials and Methods

#### 1. Study sites

Two dairy farms (farm A and B; Figure 1) in eastern Hokkaido, both of which use tie-stall dairy barns with grazing management, were studied to investigate factors related to haemolactia. The number of milking cows, the mean 305-day milk yields per cow, and the mean number of births per cow at farms A and B were



Fig. 1 Photos of dairy farms (left, Farm A; right, Farm B).

## Presence of blood in cow's milk

55 and 95 head, 8,700 and 7,900 kg, and 2.7 and 2.8 head, respectively.

### 2. Colostrum milk samples

Milk samples (colostrum) from 4 cows that were calving in June 2019 at farm A were obtained every morning and evening for 4 days after calving. The birthday and number of births (head) for each of the 4 cows were September 9, 2014 (4), June 3, 2017 (1), August 3, 2017 (1), and August 20, 2017 (1), respectively.

### 3. Mastitis

Milk samples from a cow that was found to be producing pinkish milk at the time of forestripping at farm B were obtained every morning and evening for 4 days after October 12, 2019, when the cow was not being administered any medication. The suspected cause of the haemolactia in this case was mastitis. This cow had given birth to 2 calves and had been milked for 144 days since calving. The milk yield was 22.5 kg/day, and the somatic cell count (SCC) as determined by a dairy herd performance test conducted 4 days before the occurrence of haemolactia was  $2,660 \times 10^3$  cells/mL, thereby confirming a diagnosis of mastitis.

### 4. External wound

Milk samples from a cow that was found to be milking pinkish milk at the time of forestripping at farm B were obtained every morning and evening for 4 days after November 25, 2019, when the cow was not being administered any medication. The suspected cause of the haemolactia in this case was an external wound to the udder. This cow had given birth to 3 calves and had been milked for 106 days since calving. The milk yield was 27.4 kg/day, and the SCC as determined by a dairy herd performance test conducted 13 days before the occurrence of

haemolactia was  $672 \times 10^3$  cells/mL.

### 5. Estimation of blood concentration in milk

Figure 2 shows the device used to quantitatively determine the amount of blood in the milk. The concentration of blood in the milk was estimated by performing a characteristic analysis of optical absorption for about 1 min after placing the absorption cell (path length, 4 mm) containing about 1 mL of the milk into the device. The device was operated by a Bluetooth-connected smartphone running proprietary software.




Fig. 2 Simple device for quantitative determination of blood in milk.

### 6. Somatic cell count

The SCC in the milk was determined by the Breed method [1], using a microscope.

## Results

### 1. Concentration of blood and the somatic cell count in colostrum

The daily concentration of blood and the SCC in the colostrum after calving in 4 cows are shown in Figure 3. The mean concentrations of blood in the colostrum for days 1–4 after calving were  $0.0059 \pm 0.0039\%$ ,  $0.0056 \pm 0.0022\%$ ,  $0.0028 \pm 0.0027\%$ , and  $0.0035 \pm 0.0019\%$ , respectively; these values were less than 0.01%, which is the detection limit of visual inspection. The mean SCCs for days 1–4 after calving were  $30 \pm 14$ ,  $100 \pm 54$ ,  $77 \pm 29$ , and  $51 \pm 5.7 \times 10^3$  cells/mL, respectively, which were relatively low.

## Presence of blood in cow's milk

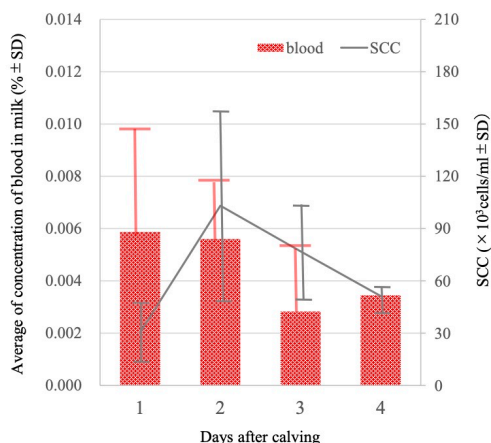


Fig. 3 Concentration of blood and SCC in colostrum from cows (n=4) for 4 days after calving.

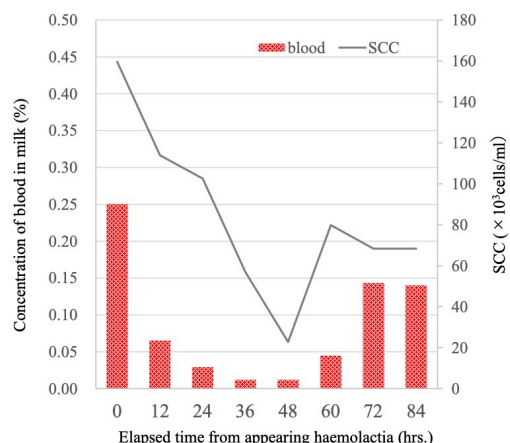


Fig. 5 Concentration of blood and SCC in the milk from the cow (n=1) with mastitis.

### 2. Concentration of blood and SCC in milk from the cow with mastitis

Milk samples were collected from a cow with mastitis every morning and evening for 4 days (Figure 4). The concentrations of blood and SCCs are shown in Figure 5. The concentration of blood ranged from 0.25% to 0.0012% over the 4 days, which gave the milk a pinkish tinge. The SCCs decreased from  $160 \times 10^3$  to  $68 \times 10^3$  cells/mL.

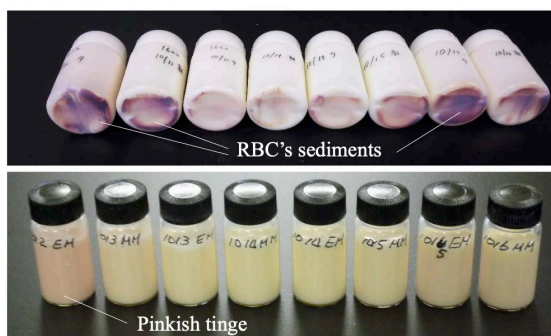


Fig. 4 Milk samples collected every morning and evening for 4 days from the cow (n=1) with mastitis.

### 3. Concentration of blood and SCC in milk from the cow with an external wound to the udder

Milk samples were collected from a cow with an external wound to the udder every morning and evening for 4 days (Figure 6). The concentrations of blood and SCCs are shown in Figure 7. The concentration of blood ranged from 0.24% to 0.011% over the 4 days; the milk was not observably pink on the 4th day by visual inspection. The mean SCC was  $51 \pm 39 \times 10^3$  cells/mL, which was relatively low.

over the 4 days; the milk was not observably pink on the 4th day by visual inspection. The mean SCC was  $51 \pm 39 \times 10^3$  cells/mL, which was relatively low.

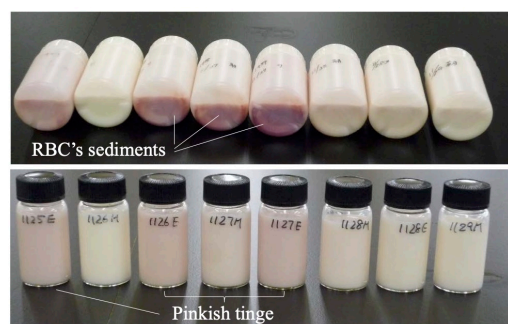

Fig. 6 Milk samples collected every morning and evening for 4 days from the cow (n=1) with an external wound to the udder.

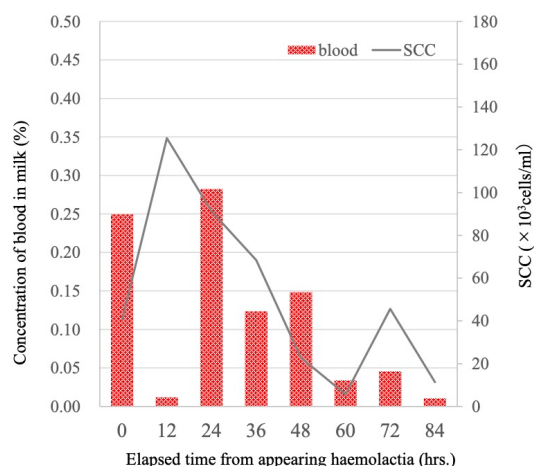


Fig. 7 Concentration of blood and SCC in milk from the cow (n=1) with an external wound to the udder.



### Discussion

To our knowledge, this study marks the first time the concentration of blood in milk was estimated at a dairy production site using a simple device. In the event that contamination of bulk milk is suspected at a dairy farm, it would be necessary to wait to ship the milk to the processing facility until an analysis using the centrifugation method could be performed at an inspection facility. By using the simple device examined in this study, it should be possible to quickly determine whether or not the milk can be shipped to the processing facility. In addition, when contamination is confirmed, the cow responsible for the contamination could be quickly identified. The main advantage of this device is that it enables detection of the presence and concentration of blood in milk easily and irrespective of the skill of individual inspectors. Previously, the presence of blood was determined only by visual confirmation, and the concentration was not quantified.

In a future study, we will investigate the relationship of occult blood in milk with data on milk quality and the physiological conditions of dairy cows.

### References

- [1] BREED, R. S., *Centralb. f. Bakt. Part II* 30: 337-340. 1911.
- [2] Fraile L., Arcas A., Jimenez L., Mallo J. and Armengol R.(2019) Treatment with etamsylate reduces haemolactia in lactating dairy cows, *Journal of Dairy Research* 86:193-195.
- [3] Hamazaki K., Fujimoto S. and Hatanaka M.(2013) Effect of administration of progesterone preparation for haemolactia in dairy cows (in Jpn.). *The Japanese Society of Farm Animal Veterinary Medicine (Kinki)*, Excellent research award <http://www.kinrenju.jp/housyou/H25.E.a.pdf>.
- [4] Hokkaido Dairy Milk Recording and Testing Association (2015) Investigation of the inspection for blood contamination in milk (in Jpn). [https://www.hmrt.or.jp/report2/report2\\_2](https://www.hmrt.or.jp/report2/report2_2)
- [5] Kikuchi T., Ichijo T., Yoshida Y., Kohono M., Murayama I, Takahashi C., Kimura Y. and Satoh H.(2013) Bloody milk of the dairy cow: occurrence and somatic cell profiles in Miyagi Prefecture (in Jpn.). *Jpn. J. Large Anim. Clin.* 4(4):154-159
- [6] Nagahata H. (2002) Bloody milk, Hemorrhage into gland, 662, Koiwa M (Eds.) *Clinical Medicine of Cattle Based on Major Symptoms*, (in Jpn.), Dairyman, Hokkaido
- [7] Saranya K.(2019). Management of blood in milk condition in postpartum dairy cow. *Int. J. Curr. Microbial. App. Sci.* 8(4):2622-2623.

### 研究ノート

#### 乳牛における簡易型検査装置を用いた血乳の発生に関する現況調査

猫本健司<sup>1</sup>・吉田夢<sup>1</sup>・大城萌乃果<sup>1</sup>・笹嶋由衣<sup>1</sup>・菅原崇<sup>2</sup>・四宮紀之<sup>2</sup>・田村知久<sup>2</sup>

1 酪農学園大学 農食環境学群, 北海道江別市, 069-8501

2 とかち財団, 北海道帯広市, 080-2462

酪農現場では、乳房内出血による血乳が搾乳されることがある。一般的に血乳は前搾り時に発見できるため、生乳出荷事故につながることは少ないが、その場で廃棄されるため、原因や血液混入割合などの詳細が明らかではない。本研究では、とかち財団が開発している簡易型血乳検査装置を用いて、現場での現況調査を実施した。調査対象は釧路地方の2酪農場において、2019年6月に分娩した4個体から搾乳した「①初乳」ならびに、同年10～11月に、前搾り時に血乳と判断された個体乳（「②乳房炎」、「③乳房の打撲」が原因と推定される血乳が突発的に生じたそれぞれ1個体）とした。これらの血液濃度を同装置で推定した上で、体細胞数をブリード法により測定した。分娩後3日目における「①初乳」中の推定血液濃度は $0.0028 \pm 0.0027\%$ で、目視（色沢）で確認できる限界濃度（約0.01%）より低かった。「②乳房炎」が原因と推定される血乳の推定血液濃度は0.25～0.012%で、明らかなピンク色を呈し、出血前の体細胞数は2,660[千個/ml]と高い値であった。「③乳房の打撲」が原因と推定される血乳の体細胞数は $51 \pm 39$ [千個/ml]と比較的低いことから、炎症性の可能性は低いと推察された。その後4日間の推定血液濃度は0.24～0.011%で、日にちの経過とともに低下した。

キーワード：血乳、血乳症、初乳、乳房炎、酪農場

受領日：2020年9月9日 受理日：2020年10月26日

日本畜産環境学会会誌 No20(1) pp10-15. 2021

No.19/20合併号としての発刊に伴い、掲載ページが改訂されました。No19/20(1) pp50-55. 2021