The Journal of Veterinary Medical Science

NOTE

Wildlife Science

Surgical removal of cataract in an Asiatic black bear (*Ursus thibetanus*) by phacoemulsification and aspiration

Seiya MAEHARA[1)]*, Naoya MATSUMOTO[2)], Naoaki TAKIYAMA[3)], Yoshiki ITOH[4)], Yasunari KITAMURA[5)], Kazuto YAMASHITA[1)], Tadashi SANO[1)], Takaharu ITAMI[1)], Norihiko OYAMA[1)], Miri HAYASHI[1)], Reiko KATO[1)], Arisa SHIMODE[1)] and Arisa MASUKO[1)]

[1)]Department of Small Animal Clinical Sciences, School of Veterinary Medicine, Rakuno Gakuen University, 582 Bunkyodai-Midorimachi, Ebetsu, Hokkaido 069-8501, Japan
[2)]Noboribetsu Bear Park, 224 Noboribetsu Onsen-cho, Noboribetsu, Hokkaido 059-0551, Japan
[3)]Veterinary Eye Clinic Nagoya, 3-16-1, Honjitori, Minami-ku, Nagoya, Aichi 457-0074, Japan
[4)]Department of Veterinary Ophthalmology, Faculty of Veterinary Medicine, Okayama University of Science, 1-3 Ikoinooka, Imabari, Ehime 794-8555, Japan
[5)]Yakumo Animal Hospital, 91, Shinonome-cho, Yakumo-cho, Hokkaido 049-3105, Japan

J. Vet. Med. Sci.
82(6): 740–744, 2020
doi: 10.1292/jvms.19-0639

Received: 28 November 2019
Accepted: 31 March 2020
Advanced Epub:
14 April 2020

ABSTRACT. A twenty-year-old male Asiatic black bear (*Ursus thibetanus*) presented at the Rakuno Gakuen University Animal Medical Center with a 10-year history of bilateral blindness and cataracts. Surgical treatment of bilateral cataracts by extracapsular lensextraction using phacoemulsification and aspiration (PEA) was performed under general anesthesia. An anterior capsulectomy was performed using micro iris scissors and micro anterior lens capsule forceps. The cataract was removed with PEA using the two-handed technique. After surgery, systemic corticosteroids, anti-inflammatory drugs and antibiotics were administered. After cataract removal, the bear had recovered vision, and good quality vision has been maintained to date (15 months). PEA can be a safe and effective treatment for cataracts that impair vision in bears.

KEY WORDS: bear, cataract, phacoemulsification and aspiration, *Ursus thibetanus*

There are few scientific reports about ocular diseases in the bears [2, 10, 12]. Hartley reported about ocular disease in bear [6]. In this report, 100 bears included Asiatic black bear, Malayan sun bear, Eurasian brown bear and Tibetan brown bear were examined, and cataract was detected in 25 bears. In the other report by Hartley, cataract surgery in bears was report [7]. But these report are presentation in conference, there is no detailed scientific report on cataracts and their treatment in bears. In the present study, we describe cataract removal using phacoemulsification and aspiration (PEA) in an Asiatic black bear.

A twenty-year-old male Asiatic black bear (*Ursus thibetanus*) presented at Rakuno Gakuen University Animal Medical Center from Noboribetsu Bear Park in Hokkaido, Japan with opacity in both eyes (OU) that had lasted approximately 10 years. This bear was born in another bear farm in Japan, and brought in Noboribetsu Bear park about 4 months after birth for display purpose. Body weight was 130 kg. According to an interview with the keeper, the bear could not find food at any distance, notice the keeper in front of the cage without his making sounds or come back to its own enclosure after release into a large enclosure. This bear had no history of systemic disease.

Ophthalmic examinations including visual tests, chromatic pupillary light reflex (PLRs) tests and dazzle reflex tests were performed. Other ophthalmic examinations including tonometry using a rebound tonometer (Tono Vet, Medtronic, Solan, FL, USA), slit lamp biomicroscopy (SL 17, Kowa, Nagoya, Japan), ultrasonography (HI VISION Preirus, Hitachi, Chiba, Japan) and electroretinography (ERG, LE-3000, TOMEY, Nagoya, Japan) were performed under sedation using a combination of 250 mg tiletamine hydrochloride and 250 mg zolazepam hydrochloride (Zoletil 100, VIRBAC, Milperra, Australia) and 160 mg xylazine (Selactar 2%, Bayer, Tokyo, Japan) IM. As a visual evaluation, a negative response to hand movement with and without pellet feed was noted. Bilateral positive dazzle reflexes and PLRs were detected in white light. The intraocular pressure (IOP) of the right eye (OD) was 15 mmHg, and the IOP of in the left eye (OS) was 16 mmHg. In slit lamp biomicroscopy, whole lens opacity and an irregular lens anterior capsule were detected, but no corneal lesion, anterior chamber flare or obvious lens luxation was revealed

*Correspondence to: Maehara, S.: seiya-m@rakuno.ac.jp

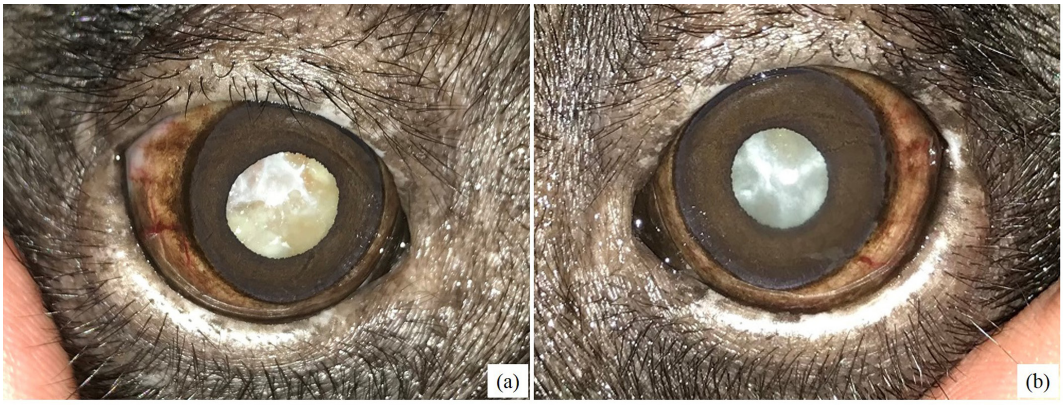

Fig. 1. Photographs before surgery of right eye (a) and left eye (b). Entire lens opacity was observed in both eyes.

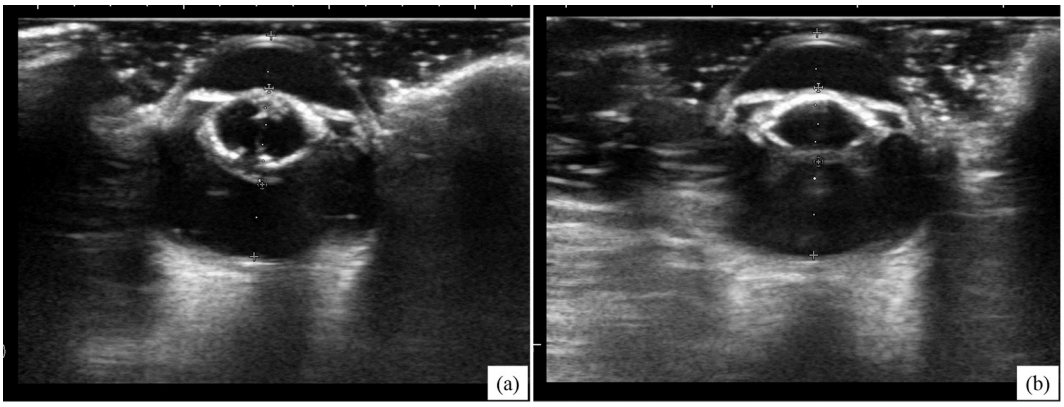

Fig. 2. Preoperative ultrasound examination findings of right eye (a) and left eye (b). High echo density was detected in the entire lens in both eyes. The ocular axial length was 15.2 mm for both right eye and left eye, and lens thickness right eye and left eye was 5.2 and 5.1 mm, respectively.

in either eye (OU) (Fig. 1). On ultrasonography, opacity of both lenses was observed, but no other abnormalities were detected. Ocular axial length was 15.2 mm for both OD and OS, and the lens thicknesses of OD and OS was 5.2 and 5.1 mm, respectively (Fig. 2). We recorded only light-adapted ERG. Single flash cone ERG and 30 Hz flicker ERG were recorded using 3.0 cd/m^2/sec stimulus strength with a 25 cd/m^2 background stimulus. Single flash cone and 30 Hz flicker ERG waveform were detected in OU (Fig. 3). From these ophthalmic examination results, the bear was diagnosed with blindness due to bilateral hypermature cataracts. Cataract surgery for both eyes was planned to restore his vision.

Cataract surgery was performed under general anesthesia. The bear had no abnormalities in pre-operative physiological and blood examinations. Blood examinations were included complete blood count (WBC, RBC, Hb, Ht, MCV, MCH, MCHC, and PLT) and blood chemical examination (TP, Alb, AST, ALT, γ-GTP, ALP, LDH, CPK, AMY, T-Cho, BUN, Cre, Na, Cl, K, Ca, and Fe). The bear's risk of general anesthesia was judged class 2 by American society of anesthesiologists physical status classification because of age. A combination of 250 mg tiletamine hydrochloride, 250 mg zolazepam hydrochloride, and 100 mg xylazine was injected by blowgun. After immobilization, 0.5% tropicamide and 0.5% phenylephrine (Mydrin-P, Santen, Osaka, Japan) were administered to OU. The mydriatic drugs were administered 3 times every 20 min starting 60 min before surgery. A 14.0-mm diameter endotracheal tube was inserted, and anesthesia was maintained with sevoflurane in oxygen.

The bear was placed in the dorsal recumbent position during cataract surgery. Both eyes were washed with 4 ppm ozonated physiological saline solution for antisepsis, and the skin around the eyes was disinfected with 10% iodine. Cataract surgery was performed using the same procedure as that for canine cataracts at our university. The surgery performed using surgical microscope (OMS-800, TOPCON, Tokyo, Japan). First, the eyelid was retracted with a speculum. The dorsal conjunctiva was separated from the sclera approximately 60° degrees. Since the bear's eyeballs were rotated towards the dorsal side under the influence of anesthesia (Fig. 4), supporting threads were placed in the dorsal rectus muscle using 6–0 silk (MANI, Tochigi, Japan). A three-step scleral incision was performed 2-mm posterior to the superior limbus (at 12 o'clock) using a microsurgical blade (Micro Feather 7340G, Feather, Osaka, Japan), crescent knife (Crescent knife MCU 26, MANI), and slit knife (Slit knife MSL 20, MANI). Two side-ports were created using a 20-gauge V-lance (MVR knife MVR 20SK, MANI) at 2 and 10 o'clock positions at the limbus. We made two side-ports in each eye for lens cortex aspiration and viscoelastic agent removal using a bi-manual handpiece. The anterior chamber was

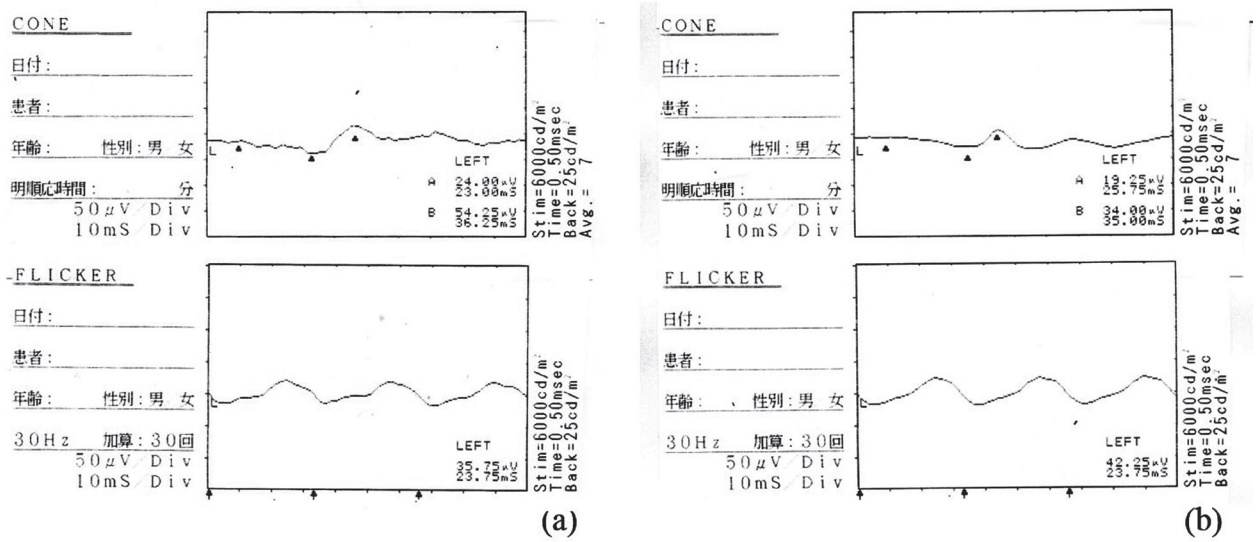

Fig. 3. Single flash cone electroretinogram (ERG, top) and 30 Hz flicker ERG (bottom) waveforms of right eye (a) and left eye (b). Both Single flash cone and 30 Hz flicker ERG waveform were recorded in both eye.

reformed and maintained using a hyaluronic acid ophthalmic viscoelastic device (Hyaluronic Acid Na 0.85 Ophthalmic Viscoelastic Substance 1% TEVA, Takeda, Osaka, Japan). The anterior lens capsule was dyed with 0.1% trypan blue (0.5%-Trypan Blue Stain Solution, Nacalai Tesque, Kyoto, Japan). Anterior continuous curvilinear capsulorhexis was performed using micro iris scissors and micro anterior lens capsule forceps. The lens material was removed with PEA using a two-handed technique, and 0.0184% BSS PLUS 500 Intraocular Irrigating Solution (Alcon, Tokyo, Japan) was used as the irrigating solution. Additionally, 0.6 mg epinephrine (BOSMIN INJECTION, Daiichi Sankyo Healthcare, Tokyo, Japan), 600 IU heparin (Heparin Sodium, Mochida, Tokyo, Japan) and 200 mg cefazolin (Cefamezin α, LTL Pharma, Tokyo, Japan) were mixed in 500 m*l* irrigation solution. The PEA was performed using phacoemulsification machine (Stellaris PC, Bausch Lomb, Tokyo, Japan). The power of ultrasound and aspiration rate during phacoemulsification for removing the lens nucleus were set at 25 to 40% and 250 mmHg, respectively. The phacotime was 6 min 24 sec for the right eye and 4 min 14 sec for the left eye. The aspiration pressure during irrigation and aspiration for removing the lens cortex was set at a maximum of 300 mmHg. The total irrigation solution used was approximately 1,200 m*l* for both eyes. An intraocular lens was not inserted. The scleral incision, conjunctival incision and side-ports were closed with 9–0 polyglactin 910 (VICRYL, ETHICON, Tokyo, Japan) interrupted sutures (Fig. 5). Operation time from incision to suture was approximately 80 min for the right eye and approximately 60 min for the left eye.

Fig. 4. Right eye when the bear was anesthetized and fixed supine. The bottom side of the photograph is the dorsal side of the eye. The eyeballs were rotated toward the dorsal side under the influence of anesthesia.

Post-operation, the bear was kept alone in own enclosure, and the bear had been banned from bathing for 1 week and from watering the head for 1 month. Postoperatively, prednisolone (PREDNISOLONE TABLETS 5 mg, Takeda) was administered at 80 mg/day orally for 2 weeks, 40 mg/day for 1week, and 20 mg/day for 1 week as an anti-inflammatory drug. Ofloxacin (Tarivid 100 mg, Daiichi Sankyo Healthcare) was administered at 800 mg/day orally for 3 weeks for prevention of infection, and aldioxa (ALDIOXA TABLETS 100 mg TOWA, Towa, Osaka, Japan) was administered at 200 mg/day orally for 4 weeks for gastric mucosal protection.

After surgery, for evaluating intraocular inflammation, we took photographs of the eyes and evaluated anterior chamber, iris color and pupil size. Two weeks after surgery, mild intraocular hemorrhage was observed so we thought intraocular inflammation remained in OU. But the bear became able to find large items of food easily, to follow the movements of keepers with its eyes, and to go to a paddock and back to its own pen. One month after surgery, intraocular hemorrhage that was observed 2 weeks after surgery had disappeared, with no abnormality of iris color and pupil size, so we thought intraocular inflammation was improved in OU. The bear now has good quality vision in OU, 15 months after surgery (Fig. 6).

This report describes surgical treatment for bilateral cataracts in an Asiatic black bear. To our knowledge, this report is the first scientific report on surgical treatment for cataracts in the bear.

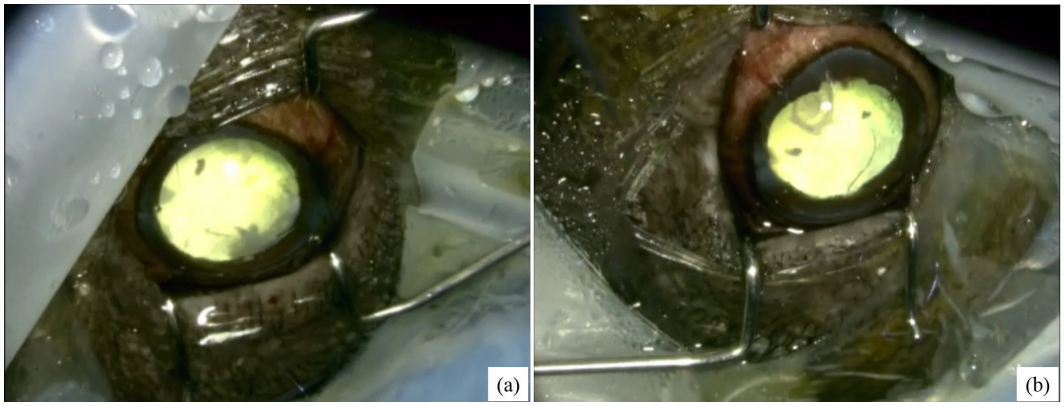

Fig. 5. Photographs after cataract removal of right eye (a) and left eye (b). The bottom side of the photographs is the dorsal side of the eye. In both eyes, cataract was removed, but the anterior capsule opacity partially remained.

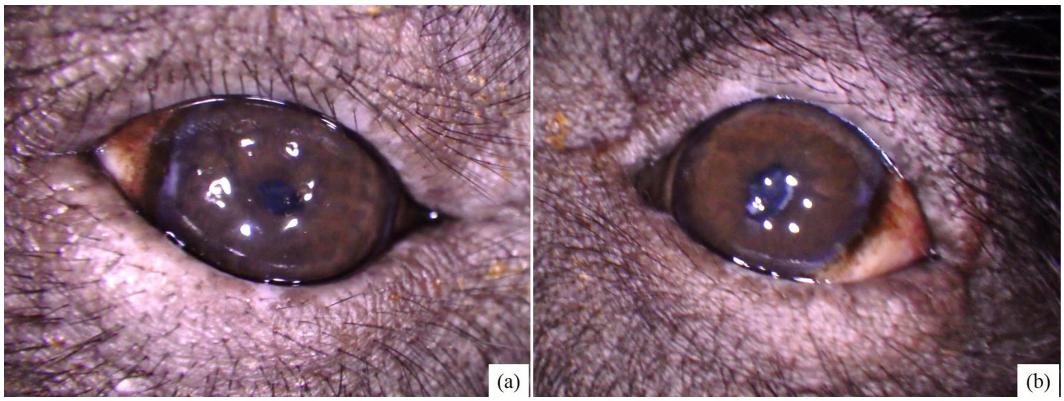

Fig. 6. Photographs 15 months after cataract removal of right eye (a) and left eye (b).

We could not determine the cause of cataract in this bear. The cause of cataract in other species is included aging, inheritance, ocular trauma, nutrition problem, diabetes, exposure to ultraviolet and other ocular disease for example persistent pupillary membrane, uveitis or retinal degeneration and so on [1, 4, 11, 14]. Aging, trauma, nutrition problem, diabetes and other eye problems were thought to be less likely to cause of cataract in this bear, because of the age of onset cataract, the rearing environment, his systemic condition and results of the ophthalmic examination. However, heredity and exposure to ultraviolet were not ruled out as the cause of cataract.

It was difficult to obtain scotopic ERG waveforms that require dark-adaptation, only photopic ERG waveforms were examined in this case. The normal value of ERG parameters in bears has not been reported. Although the recorded ERG waveforms were not able to judge as normal, the results of light-adapted ERGs indicated that both retinas had function under photopic condition. To establish the normal values of ERG parameters in bear, further reports are needed.

Since it is dangerous to administer eye drops to a conscious bear, immobilization was performed after administration of an anesthetic agent, and mydriatic eye drops were instilled. Administration of mydriatic drug three times achieved sufficient mydriasis to perform PEA, although the ophthalmic pharmacodynamics are not known in bears. In this case, 0.5% tropicamide and 0.5% phenylephrine were utilized, and it was found that these drugs can be used as mydriatic agents not only in dogs, cats and horses but also in bears [8].

Because of the animal's age and long history of cataracts, the lenses might have been too dense to perform PEA, and extracapsular lens extraction was also considered for the surgical procedure. However, the cataractous lens materials were removed by PEA in this case. It is difficult to administer eye drops and fit an Elizabethan collar postoperatively, and PEA with a small incision may be beneficial for control postoperative ocular pain and infection in bears.

There are some reports of globe size in bears, that reported an axial length of 18.5 mm and 18.0 mm in the American black bear and brown bear, respectively [9, 10]. In this case, the ocular axial length was 15.2 mm in both eyes, which is much smaller than those in adult dogs and cats [13]. Hartley reported artificial intraocular lens implantation in bears using canine and feline lenses [7]. But an artificial intraocular lens was not inserted in our case, because there are no reports on the refractive power in the Asiatic black bear. Failure to perform intraocular lens implantation after cataract removal results in hyperopia in dogs and cats [3], this case also was presumed to be hyperopic after surgery. In fact, the bear became able to find large items of food easily

postoperatively but still had difficulty finding small items of food placed nearby, as it had before surgery.

Both topical and systemic antibiotics continued for 7 to 10 days after cataract surgery are recommended in dogs [3]. Because of the difficulty of applying eye drops, only oral postoperative medication for controlling inflammation and preventing infection was utilized in this case. Prednisolone at 80 mg/day was administered initially for reducing postoperative iridocyclitis and stabilizing the blood-aqueous barrier, which was the same as for canine cataract surgery [3]. Since a detailed treatment protocol for uveitis in the Asiatic black bear has not been reported, the dose of prednisolone was determined based on treatment for allergic dermatitis in the polar bear [5]. Aldioxa as a gastric mucosa protective agent was used in combination, and no serious systemic side effects were observed during the administration of prednisolone.

Postoperative inflammation, infection and glaucoma are considered serious complications of cataract surgery that may lead to irreversible loss of vision. Detailed ophthalmic examinations to evaluate ocular inflammation and infection and tonometory could not be performed in this case. However, no obvious signs of these complications were observed from 1 month after surgery. We thought that if some training for eye drop and examination were performed we might be able to detailed postoperative evaluations. Both administration of eye drops and detailed eye examination are essential to decrease surgical complications and management. Husbandry training is required to perform special treatment and examination in zoo and/or aquatic animals, but it may be more difficult in blind animals. Though husbandry training was attempted in this case, eye drop treatment and eye examination could not be performed when this case was conscious. Topical medication with or without systemic medication for controlling postsurgical uveitis is ideal to minimize systemic side-effects. Systemic side-effects were not examined by blood analysis in this case, but obvious side-effects such as diarrhea, bloody stools were not observed. The post-surgical eye conditions were evaluated by observation from outside of the enclosure such as blepharospasm, haze in cornea and anterior chamber, pupil shape and size. Further study is needed to establish standardized postoperative treatment and evaluation for cataract surgery in bears.

Objective examination to evaluate vision is not established in bears. However, this bear's visual acuity seemed to recover dramatically based on its behavior. This result indicates that PEA can be a safe and effective treatment for cataracts that impair vision in bears. Further investigations of the surgical procedure and perioperative treatment of cataract surgery and objective examination for evaluating visual status in bears are needed.

In this study, we report successful cataract surgery in an Asiatic black bear. There are about 20 brown bears in the Bear Farm that have retired from public viewing because of their age. Some of these bears also suffer from cataracts and have reduced quality of life due to visual impairment. We hope that this report will lead to many cataract operations for bears with visual impairment due to cataracts.

REFERENCES

1. Davidson, M. G. and Nelms, S. R. Disease of lens and cataract formation. pp. 1199–1233. *In*: Veterinary Ophthalmology, 5th ed. (Gelatt, K. N., Gilger, B. C. and Kern, T. J. eds.), Wiley-blackwell, Ames.
2. Dombrowski, E., McGregor, G. F., Bauer, B. S., Parker, D. and Grahn, B. H. 2016. Blindness in a wild American black bear cub (*Ursus americanus*). *Vet. Ophthalmol.* **19**: 340–346. [Medline] [CrossRef]
3. Gelatt, K. N. and Wilkie, D. A. 2011. Surgical procedures of the lens and cataract. pp. 305–355. *In*: Veterinary Ophthalmic Surgery, (Gelatt, K. N. and Gelatt, J. P. eds.), Elsevier, Amsterdam.
4. Gilger, B. C. Equine ophthalmology. pp. 1560–1609. *In*: Veterinary Ophthalmology, 5th ed. (Gelatt, K. N., Gilger, B. C. and Kern, T. J. eds.), Wiley-blackwell, Ames.
5. Harper, J., White, S., Stewart, L. and Pelto, J. 1988. Inhalant allergic dermatitis in bears. *Proceedings of the Annual Meeting of the American Association of Zoo Veterinarians*. 97–98.
6. Hartley, C., Donaldson, D., Bacon, H., Officer, K., Bando, M., O'Dwyer, J., Reynard, J., Leadbeater, W., Field, N., Nelson, C., Hall, K., Elliot, V., Gorman, E., Walters, H., Ryan, K., Perrin, K., Kingston, R., Gasson, J., Weegenaar, A., Wicker, F., Meilvang, A. S., Quine, H., Bendixsen, T. and Robinson, J. 2014. Ocular findings in asiatic black bears (Ursus thibetanus), Malayan sun bears (Helarctos malayanus), Eurasian brown bears (ursus arctos arctos), and a Tibetan brown bear (Ursus arctos pruinosus) rescued from the bile farming industry & wildlife trade in Asia. *Vet. Ophthalmol.* **16**: E36.
7. Hartley, C., Donaldson, D., Bacon, H., Officer, K., Bando, M., O'Dwyer, J., Reynard, J., Leadbeater, W., Field, N., Nelson, C., Hall, K., Elliot, V., Gorman, E., Walters, H., Ryan, K., Perrin, K., Kingston, R., Gasson, J., Weegenaar, A., Wicker, F., Meilvang, A. S., Quine, H., Bendixsen, T. and Robinson, J. 2014. Ocular surgeries in Asiatic black bears (Ursus thibetanus) and a Malayan sun bear (Helarctos malayanus) rescued from the bile farming industry & wildlife trade in Asia. *Vet. Ophthalmol.* **16**: E36.
8. Herring, I. P. 2013. Clinical pharmacology and therapeutics Prat 4: mydriatics/cycloplegics, anesthetics, and tear substitutes and stimulators. pp. 423–434. *In*: Veterinary Ophthalmology, 5th ed. (Gelatt, K. N., Gilger, B. C. and Kern, T. J. eds.), Wiley-blackwell, Ames.
9. Kirk, E. C. 2006. Eye morphology in cathemeral lemurids and other mammals. *Folia Primatol. (Basel)* **77**: 27–49. [Medline] [CrossRef]
10. Mainka, S. A. and Christmas, R. 1987. Ocular nodular fasciitis in an Asiatic Black bear (*Selenarctos thibtanus*). *J. Zoo Anim. Med.* **18**: 156–158. [CrossRef]
11. Pearce, J. W. and Moore, C. P. Food animal ophthalmology. pp. 1610–1674. *In*: Veterinary Ophthalmology, 5th ed. (Gelatt, K. N., Gilger, B. C. and Kern, T. J. eds.), Wiley-blackwell, Ames.
12. Sakai, H., Goto, M. and Komatsu, T. 2017. Basal cell adenocarcinoma in the gland of the third eyelid of a brown bear (*Ursus arctos*). *J. Vet. Med. Sci.* **79**: 1348–1351. [Medline] [CrossRef]
13. Samuelson, D. A. 2013. Ophthalmic anatomy. pp. 39–170. *In*: Veterinary Ophthalmology, 5th ed. (Gelatt, K. N., Gilger, B. C. and Kern, T. J. eds.), Wiley-blackwell, Ames.
14. Stiles, J. Feline ophthalmology. pp. 1477–1559. *In*: Veterinary Ophthalmology, 5th ed. (Gelatt, K. N., Gilger, B. C. and Kern, T. J. eds.), Wiley-blackwell, Ames.